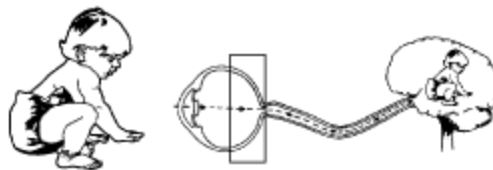




Serving children with visual impairments and their families since 1949

Pediatric Visual Diagnosis Fact Sheet™

RETINOPATHY OF PREMATUREITY



DEFINITION

Retinopathy of Prematurity (ROP) is an eye disorder affecting premature infants. This disorder was called Retrolental Fibroplasia in the past.

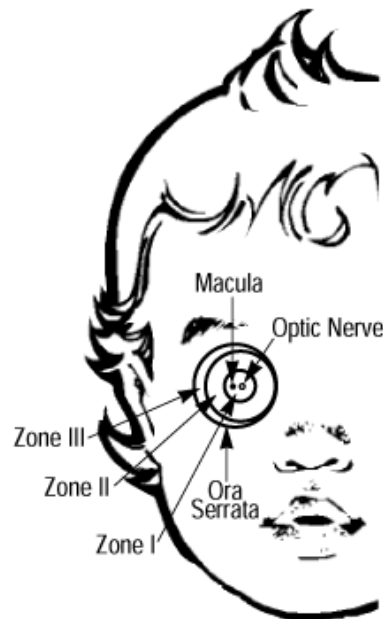
ROP affects immature blood vessels of the retina. It occurs weeks after birth. Once development of blood vessels is complete, a child is no longer a candidate for this disorder.

As pictured in the graphic of the retina:

Zone One is centered on the Macula (which is the area of central vision needed for reading).

Zone Two refers to an area that is doughnut shaped that extends to the edge closest to the nose.

Zone Three refers to the crescent shaped area toward the ear. If disease appears in **Zone One** (as can happen with extremely low birthweight infants), damage to the retina tends to be more severe. If **Zone Three** is affected, the premature infant will tend to have mild involvement, leading to useful vision.



CAUSES

The suggested causes of Retinopathy of Prematurity are those conditions which stop the orderly growth of retinal blood vessels and stimulate their wild overgrowth.

Over 50 conditions have been proposed and thus far, have not been ruled out. The most frequently mentioned conditions are prematurity, excessive oxygen, infection, and/or excessive exposure to light.

STAGES OF RETINOPATHY OF PREMATURITY

Normal retinal development consists of gradual, uninterrupted growth of blood vessels supplying the retina.

STAGE NO.	CHARACTERISTIC:
1	Partial vascularization with distinct demarcation line.
2	Ridge develops at demarcation line, stopping normal vascular development.
3	Blood vessels within ridge grow wildly toward center of eye, and scar tissue develops.
4	Scar tissue pulls the retina, causing partial detachment.
5	Total retinal detachment.

TREATMENT

It is critical that doctors examine the retinas of premature infants until blood vessels have reached the edge of the retina.

One or more of the following treatments have been suggested to stop the overgrowth of blood vessels or to reattach the retina: cryotherapy (the only treatment proven by rigorous testing), laser treatment, scleral buckling, and vitrectomy.

CHARACTERISTICS

Children with an initial diagnosis of ROP are at risk for developing secondary visual impairment including cataracts, glaucoma, and retinal detachment. Other eye conditions such as myopia, nystagmus, strabismus, or microphthalmia may also occur. Children with

ROP may exhibit other impairments associated with extreme prematurity, such as cortical visual impairment, cerebral palsy, or learning disabilities.

VISUAL AND BEHAVIORAL CHARACTERISTICS

Many of the behaviors of children with ROP may be related to prematurity and not necessarily to vision loss. Learning difficulties associated with neurological disorders may accompany prematurity. These may show up in areas of abstract reasoning, for instance, or in the child's unwillingness to touch and handle certain textures. The way a premie with ROP understands his position in space, or the manner he uses to walk (gait) may also be different than that of a child who has a different visual diagnosis. Eye pressing, body rocking, head swiveling or hand flapping are also part of the behavior pattern some children with visual impairments exhibit.

A child with ROP may use a head tilt or unusual body position to accommodate for poor vision, vision in one eye (monocular vision), or a reduced visual field. In addition, research suggests that blue-yellow color deficits in children who have ROP are 200-2000 times that of the general population.

MYTHS

The following statements are **NOT TRUE**, according to current knowledge in the field:

- ROP no longer occurs since oxygen levels have been adjusted in the intensive care nursery.
- Surgery can cure ROP.
- A reattached retina means that normal vision will be restored.
- Repetitive mannerisms often seen in children with ROP indicate autism.

TEACHING STRATEGIES

- A multisensory teaching approach is helpful with the child who has ROP. Whenever possible combine the use of vision with tactual, kinesthetic and auditory input to maximize the learning process.
- By using real objects when playing and working with the child with ROP and by involving the child in the processes of life, such as cooking or dressing, the child will develop more meaningful language and a better understanding of the way the world works.
- Since the child with ROP may not see a great distance, spoken information will help him understand the actions of people and things around him. Describe pictures in books, the actions of others, people's body language and gestures, or strange and unusual sounds.
- Provide ongoing assessment of all areas of development and of individual learning styles. For the child with ROP, assessment of learning style is especially critical, to determine the best materials for learning.
- Help the child to develop good listening skills to supplement his use of remaining (residual) vision.
- A child with ROP may use unusual body positions to see better. Sometimes this

leads to fatigue. For the school age child with ROP, some adaptive strategies such as using a slant board for looking at books, holding a finger on the line of print when reading, or using a reading window (typoscope) will be helpful in relieving fatigue and poor posture.

- Since a child with ROP often has some loss of peripheral vision, it is important that he learn to examine the environment consciously and in a systematic way (scanning) to compensate for this.
- Materials that have high contrast are often easier for a child with ROP to see.
- Since the vision of the child with ROP may change over his lifetime, it is important to evaluate the child's abilities over the years. For the same reason, Braille should be considered as a primary or secondary reading medium
- The child with ROP will benefit from the services of an Occupational Therapist trained in sensory motor integration and/or a specialist in Orientation and Mobility, as appropriate.

GLOSSARY

1. Cryotherapy: a treatment that freezes the abnormal part of the retina.
2. Kinesthetic: describes the sensation of position and movement of parts of the body.
3. Laser treatment: process that destroys abnormal retina.
4. Macula: part of the retina directly behind the lens, which is responsible for central vision.
5. Microphthalmia: abnormally small eyes.
6. Myopia: near-sightedness.
7. Nystagmus: involuntary rhythmic eye movements.
8. Retina: inner light-sensitive layer of the eye.
9. Retinal detachment: part or all of the light-sensitive retina comes away from the wall of the eye.
10. Sclera: outer layer of the eye; the "white" of the eye.
11. Scleral buckling: a procedure which places a belt around the outside of the eye. The belt is tightened until the retina is close enough to the wall to reattach itself.
12. Strabismus: condition in which the eyes are not aligned.
13. Vitrectomy: a surgical procedure in which the eye is opened up, the lens is removed and some or all of the vitreous humor is removed so the surgeon can reattach the retina.

RESOURCES

Cryotherapy for Retinopathy of Prematurity Cooperative Group (1994). The Natural Ocular Outcome of Premature Birth and Retinopathy of Prematurity, *Archives of Ophthalmology* 112, 903-912.

Fansler, L. (1993). A Parent Discusses Self Stimulation, P.S. News!!! Texas School for the Blind, Austin, TX.

George S. et al, (1988). The Latest on Retinopathy of Prematurity, *Maternal Child Nursing* 13, 254-258.

Hack, M. (1994). School Age Outcomes in Children with Birth Weights Under 750 g, The New England Journal of Medicine, 331, no. 12, 752-759.

Hammer, E. (1993). Dr. Hammer Responds, P.S. News!!! Texas School for the Blind, Austin, TX.

McNamara, A. de Juan, E. & Varley, M., (1991). Understanding Retinopathy of Prematurity, IRIS Medical Instruments, Inc. CA.

Moss, K. (1994). Looking at Self Stimulation in the Pursuit of Leisure or I+m Okay, You Have a Mannerism, P.S. News!!! Texas School for the Blind, Austin, TX.

Page, J. et al (1993). Ocular Sequelae in Premature Infants, Pediatrics, 92, 787-790.

Quinn, G. et al (1991). Visual Acuity in Infants after Vitrectomy for Severe Retinopathy of Prematurity,

Ophthalmology, 98, #1, 5-13.

Silverman, William (1980). Retrolental Fibroplasia, A Modern Parable, Grune and Stratton, Inc. New York.

Trief, E. (1989). Retinopathy of Prematurity, Journal of Visual Impairment and Blindness, Dec., 500-504.

ACKNOWLEDGMENTS

Project Coordinator, Julie Bernas-Pierce M.Ed.

Liz Barclay, Pat Eagle, Namita Jacob, Dennak Murphy, Sharon Sacks, Ph.D.,

Dr. William Silverman, Donna Shimada. Reviewers: Dr. Earl Palmer,

Helen Harrison, Dr. William Good, Kathryn Neale Manalo

The Pediatric Visual Diagnosis Fact Sheets are sponsored by a grant from the Blind Children's Center and with support from the Hilton/Perkins Program through a grant from the Conrad Hilton Foundation of Reno, Nevada

REPRODUCTION FOR RESALE IS STRICTLY PROHIBITED (1/98 BBF)

Article is used courtesy of Blind Babies Foundation.

Main BBF Office:

Blind Babies Foundation

5016 Mission St.

San Francisco, CA 94112

Website: <http://blindbabies.org>