

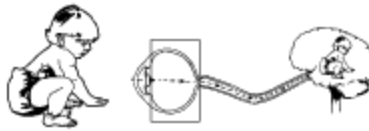


BLIND BABIES FOUNDATION (BBF)

Serving children with visual impairments and their families since 1949

Pediatric Visual Diagnosis Fact Sheet™

RETINAL DISEASES



DEFINITION

The **retina** is the innermost coating of the eye, containing light-sensitive nerve cells and fibers connecting with the brain through the optic nerve. The retina is held in place by the pressure of a gel (vitreous) within the eye.

Note: Retinopathy of Prematurity and Albinism, two more common retinal diseases, are addressed in individual fact sheets.

In order to understand how some retinal diseases are inherited, it is important to be aware of the following:

Patterns of Inheritance

1. Autosomal dominant: inherited from one affected* parent, with a 50% chance of each pregnancy being affected.
2. Autosomal recessive: inherited from both non-affected parents, with a 25% chance of each pregnancy being affected.
3. X-linked recessive: inherited from a non-affected mother, with a 50% chance of each pregnancy being affected. Usually only sons are affected.

*affected: when applied to a genetic disease, means the individual has the clinical disorder.

DIAGNOSIS

An ERG (electroretinogram) may be used to diagnose certain retinal diseases. Testing involves objective measurement of the retina's response to a light stimulus under well-

controlled environmental lighting circumstances. In most cases, testing takes place under normal lighting conditions as well as in the dark. In order to perform the ERG test, usually young infants need to be sedated. The pupils of the eye will be dilated and eyelids propped open. Contact lenses are placed on the eyes in order to provide the flash stimulus. Recording electrodes are taped to the scalp. The test requires a couple of hours to be completed. The ERG provides information to establish the appropriate diagnosis. It does not provide measurements that necessarily predict visual function. When performed on an infant, test results may be inconclusive, requiring retesting when the child is older.

CHARACTERISTICS

The following diseases of the retina fall into two major categories:

1. Normal Appearing Retina (Non-progressive Diseases): these conditions have characteristics which include: bilateral decreased vision; purposeless, involuntary, rhythmic eye movements(nystagmus); and an apparently normal clinical exam; however, an abnormal ERG establishes the appropriate diagnosis.

Lebers Congenital Amaurosis (LCA-also known as Cone/Rod Dystrophy): a group of disorders with little or no vision, slow nystagmus-like movements, abnormal amounts of farsightedness (3 diopters or more), and an extinguished (flat) ERG. Most of the children will have no other associated findings. However, some will be found to have kidney, brain or heart disorders, for example: Senior-Loken Syndrome or Joubert's Syndrome.

Cone Dystrophies: usually present with mild to moderate vision loss, photophobia and small amplitude nystagmus. Color vision is variably impaired.

Achromatopsia: the most common of the cone disorders presenting in infancy with reduced visual function, color blindness, light sensitivity (photophobia) and a fast moving "shimmy" of the eye (nystagmus). Tinted lenses improve visual function. This is an autosomal recessive condition with no associated abnormalities.

Congenital Stationary Night Blindness: a rod dystrophy occurring only in boys, who present with night blindness, nystagmus, decreased visual function and nearsightedness (myopia). This is an X-linked recessive inheritance with no associated abnormalities.

2. Abnormal Appearing Retina

These conditions fall into three categories:

a. Congenital and Acquired Structural Abnormalities

b. Traumatic Retinal Detachment/Hemorrhage

c. Infections

a. Congenital and Acquired Structural Abnormalities

Children with structural abnormalities of the retina present with a wide variety of syndromes and conditions.

Colobomas: congenital absence of retinal tissue (cleft or hole) caused by failure of normal

development in the sixth week of pregnancy. Visual function is dependent on the size and location of the cleft. **Vitreoretinal Dysplasia (Norries disease):** congenital disorganization of the normal structure of the vitreous and retina which usually causes blindness. This is an X-linked recessive form of vitreoretinal dysplasia associated with retardation and deafness. **Sticklers Syndrome:** autosomal dominant disorder, leading to cataracts, retinal detachment and glaucoma. These children have high myopia, which is generally non-progressive. Careful monitoring of children with Sticklers is important because early treatment of ocular complications can prevent blindness.

Retinitis Pigmentosa (RP-a rod/cone dystrophy): progressive, hereditary degeneration and wasting away (atrophy) of light sensitive cells (rods and cones) of the retina, with differing rates of progression and severity, and different modes of inheritance. RP begins with rod dysfunction only; but as the disease progresses, the cones are involved as well. RP does not present with acuity and color vision loss in early childhood, but caregivers frequently notice that children exhibit reduced peripheral vision and night blindness. RP affects approximately 1 in 4000 persons. Deafness is sometimes associated with RP, usually occurring later in life.

Retinoblastoma: malignant tumor within the eye, usually presenting before age 5, with one crossed eye (monocular strabismus) or a white spot or glow in the pupil (abnormal light reflex). Cancer of the eye is a shocking diagnosis that parents must act upon quickly. Detailed, sympathetic and repeated discussions are needed, together with support services for the parents, especially during active phases of treatment. Retinoblastoma can be hereditary or non-hereditary affecting one or both eyes (unilateral or bilateral). If detected early, retinoblastoma has one of the highest survival rates of any malignant tumor. Diagnosis may be determined by ultra-sound, CT Scan (Computed Axial Tomography), MRI (Magnetic Resonance Imaging), bone marrow aspiration and lumbar puncture. Treatment options may include radiotherapy, cryotherapy, laser therapy, chemotherapy and surgical removal of the eye (enucleation). Long-term follow up is advisable in all cases.

b. Traumatic Retinal Detachment/Hemorrhage: When detached from its normal blood supply, the retina can no longer maintain its normal activity and function.

Shaken Baby Syndrome (SBS): when an infant is forcefully shaken, detachment of the retina may occur as either the result of direct traumatic injury or as a secondary complication of intraocular bleeding. The visual impairment may be due to retinal detachment, optic atrophy, and/or damage to visual pathways in the brain.

Head Injury: a similar destructive injury, most commonly occurring in auto accidents.

c. Infections

Toxoplasmosis: infection of the eye occurring as a result of maternal exposure (during pregnancy) to a parasite present in cat feces. The brain may also be affected.

Toxocara: an acute intraocular inflammatory response to a parasite found in dog feces. The parasite causes cataracts, inflammation of the vitreous and surrounding tissues (vitritis).

Herpes: a blood-born viral infection transmitted during pregnancy and/or delivery that may cause a devastating destruction (necrosis) of the retina and brain.

Cytomegalovirus (CMV): a viral infection transmitted during pregnancy that may cause damage to the retina, brain and liver.

MYTHS

The following statements are **NOT TRUE** according to current research:

- People who are color blind have normal visual acuity.
- Bouncing a child on knee, jogging in a backpack, or falling off a bed causes Shaken Baby Syndrome.
- All children with Lebers Congenital Amaurosis have mental retardation.

EYE PRESSING AND EYE POKING

Eye pressing, poking, and rubbing are terms often grouped together and used incorrectly. Eye pressing is an important clinical finding occurring only in children with congenital, severe, bilateral retinal disorders. Children may press their eyes when they are bored or anxious, and also during various activities, such as listening to music or riding in the car. Eye pressing is not precipitated by frustration, is not painful, and tends to be prolonged (Jan, et al. 1994). Introducing activities that keep the child's hands busy may diminish eye pressing. Also, discussing strategies with families of older children with retinal disorders may be helpful. When a child is older, tactile and verbal cues can be used to discourage the behavior temporarily. Eye pressing is not considered to be self-injurious behavior, which differentiates it from eye poking. Eye pressing manifests itself as a result of retinal vision loss whereas eye poking is not limited to persons with vision impairment and may lead to vision loss.

ADAPTATIONS AND TEACHING STRATEGIES

- It is important that the child, parent, teacher, vision resource teacher, ophthalmologist, and optometrist work as a team. The team should consider positioning, seating, lighting, glare, characteristics of toys and materials, and social/emotional growth of each child when making program recommendations.
- Early and ongoing assessment of the child's vision is crucial. As a child matures in the educational system, she faces increased visual demands and smaller print size, and may benefit from suitable magnifiers, telescopes, or large print materials.
- The child with cone/rod dystrophies and/or light sensitivity may benefit from the use of tinted lenses. Tint choices may vary according to the child's diagnosis and personal preference. Hats and visors may also be helpful. A period of experimentation is often required before choosing the solution that best meets the child's needs.
- Awareness of lighting variability and its influence on the child's visual function is important. Provide preparation, time and reassurance for a child who is moving from one lighting situation to another. Provide opportunities for outdoor play during times when light is softer and more indirect, such as early morning or evening, or in shady areas. When the environment makes it difficult to see, a child must learn to rely on other senses. Bright glare from snow, sand, water, pavement, or dappled light where sun and shadows continually change, can reduce a child's visual world.
- It is important to recognize that a child's visual function varies from day to day. Additional energy and effort a child uses to process visual information can cause

fatigue, irritability, or "acting out" behaviors. Provide a variety of activities to break up the day.

- For the child who lacks color vision, use descriptive language that includes texture, shape, and form and pattern words; use terms such as light, medium and dark to describe shades of color.
- Encourage the older, verbal child to describe objects in his own words.
- Allow the child to use head and eye positions that are comfortable and work best. Children with nystagmus typically need an eye and/or head position that allows them to slow down or stop the nystagmus (null point). A child should be able to hold toys and objects as close as he would like and to move to the most advantageous viewing position.
- Provide good indirect lighting, or position a light source behind the child. Never position a child directly facing the light source. Also, parents or teachers should always position themselves so that the child is not looking toward a light source. To reduce glare on work or play surfaces use a black or non-reflective dark fabric under toys or materials. The following qualities make a significant difference in the child's ability to see printed materials:
 - High contrast
 - Uncluttered backgrounds
 - Well defined pictures Large print
- To compensate for missed nonverbal cues such as facial expression, a person waving hello or good-bye, etc. a child should be told or shown the gestures.
- To compensate for a lack of depth perception, provide a child with repeated opportunities for exploration and movement in a variety of settings and lighting conditions.
- With a child's participation, open, positive discussion at home and school regarding a vision impairment can encourage the child to acknowledge her vision needs, and to advocate for herself.
- To prevent accidental injury, protective lenses are advisable for all children with reduced vision.
- Children who undergo many medical procedures need opportunities to re-enact their experiences through play.
- Even a very young child can benefit from preparation for medical procedures. For example, identifying the sequence of events in the doctor's office may reduce a child's anxiety. Honest statements regarding each procedure build trust and assurance for the child.

GLOSSARY

1. **Cones:** light sensitive cells in the retina that process central, color, and daytime vision (photopic).
2. **Congenital:** present at birth.
3. **Cryotherapy:** a treatment that freezes the abnormal part of the retina.
4. **Diopter:** the unit of refracting power (bending of light rays) of a lens.
5. **Dystrophy:** progressive changes that may result from defective nutrition of a tissue or organ.
6. **Intraocular:** within the eye, includes the anterior chamber, iris, lens, vitreous, and

retina.

7. **Lumbar:** relating to the loins or the part of the back and sides between the ribs and pelvis.
8. **Rods:** light sensitive cells in the retina that process motion and nighttime vision (scotopic).

RESOURCES

[Achromatopsia Network](#): P.O. Box 214, Berkeley, CA 94701-0214;

FAX: (510) 540-4767

e-mail: Editor@achromat.org

Jan, JE, Freeman, RD, et al: Eye pressing by visually impaired children. *Developmental Medicine and Child Neurology* 25: 755-762, 1983.

Jan, JE, Good, Wm., et al: Eye Poking. *Developmental Medicine and Child Neurology*, 36: 321-325, 1994.

Lambert, S, Taylor, D: The Infant with Nystagmus, Normal Appearing Fundi, but an Abnormal ERG. *Survey of Ophthalmology* 34:173-185, 1989.

National Association of Parents of the Visually Impaired (NAPVI), P.O. Box 317, Watertown, MA 02272-0317.

Phone (800) 562-6265.

Retinoblastoma Support News, The Institute for Families of Blind Children, P.O. Box 54700, Mail Stop 111, Los Angeles, CA. 90054-0700.
Phone (213)669-4649.

Taylor, D, Hoyt, C: 1997, *Practical Paediatric Ophthalmology*, Blackwell Science, Inc. Cambridge, MA.

ACKNOWLEDGMENTS

Project Coordinator: Julie Bernas-Pierce
Dr. Creig Hoyt, Nancy Akeson, Gail Calvello, Catherine Wilson,
Kathryn Neale Manalo, Susana Saeidnia

The Pediatric Visual Diagnosis Fact Sheets are sponsored by a grant from the Blind Children's Center and with support from the Hilton/Perkins Program through a grant from the Conrad Hilton Foundation of Reno, Nevada.

REPRODUCTION FOR RESALE IS STRICTLY PROHIBITED (1/98 BBF)

Article is used courtesy of [Blind Babies Foundation](#).

Main BBF Office:
Blind Babies Foundation
5016 Mission St.
San Francisco, CA 94112
Website: <http://blindbabies.org>